




PHILIPS

Lead Management

Summary statement

Heart Rhythm Society 2017

Expert consensus statement¹

 Heart Rhythm Society™

Recognized as a quality educational
tool by the Heart Rhythm Society.

Table of contents

Overview	3
Key takeaways	4
Treatment	6
Periprocedural management: preparatory phase	14
Patient clinical scenarios	16
Infection diagnosis and treatment	22
Abbreviations	27

The ideas and opinions expressed in this product do not necessarily reflect those of the Heart Rhythm Society (HRS). The mention of any product, service, or therapy in this training should not be construed as an endorsement. It is the responsibility of the treating physician or other health care provider, relying on independent experience and knowledge of the patient, to determine the best treatment for the patient.

Overview

- The 2017 consensus statement focuses on providing practical clinical guidance in lead management and lead extraction to help clinicians in their decision-making process for managing leads.
- The 2017 consensus builds on the 2009 consensus document.²
- The 2009 consensus recommendations on facilities and training for lead extraction remain appropriate.
- 1.2-1.4 million CIEDs are implanted annually worldwide.
- Although recent technological advances have eliminated the need for transvenous or epicardial leads for CIEDs used in selected groups of patients, lead management remains important.
- Careful consideration with the patient on the decision on whether to abandon or remove a lead is recommended before starting the procedure. (COR I; LOE C-EO)

Developed in collaboration with:

- American College of Cardiology (ACC)
- American Heart Association (AHA)
- Asia Pacific Heart Rhythm Society (APHRS)
- American Society of Anesthesiologists (ASA)
- European Heart Rhythm Association (EHRA)
- Infectious Diseases Society of America (IDSA)
- Latin American Heart Rhythm Society (LAHRS)
- Pediatric and Congenital Electrophysiology Society (PACES)
- Society of Thoracic Surgeons (STS)

Key takeaways

Infection

- Infection remains a Class I indication for removal of all hardware.
- Extractor consult in patients with documented CIED infection. (COR I; LOE C-EO)
- At least 2 sets of blood cultures before antibiotics for suspected CIED infection. (COR I; LOE C-LD)
- Additional imaging to diagnose pocket or lead infection. (COR IIb; LOE C-LD)
- New infection management decision trees can support diagnosis and treatment.

Shared decision-making

- Discuss risks of abandonment versus risks of extraction with patients. (COR I; LOE C-EO)
- Extraction may be considered after shared decision-making process with patients. (COR IIb; LOE C-EO)
- Discuss program and operator volume, clinical success, and complication rates with patients. (COR I; LOE C-EO)

CIED management

- When preparing for CIED upgrade, a preparatory venogram or noninvasive ultrasound prior to opening the pocket to assess venous patency should be considered.
- Leave abandoned leads in a condition that permits future extraction. (COR I; LOE C-EO)
- Increase surveillance for leads with higher failure rates. (COR IIa; LOE C-EO)

Occlusive compliant balloon

- Deployment of a compliant occlusion balloon for SVC tears to help control severity of bleeding.
- Preprocedural preparation: Place a stiff guidewire and insert an introducer sheath.
- Initial studies have suggested that the occlusive balloon is safe and associated with improved survival in the setting of vascular tears of the SVC.

Treatment

Lead survival

Recommendation	COR	LOE
A lead model and clinical scenario-specific strategy of increased surveillance and management can be useful for CIED leads that have been identified with higher-than-expected failure rates.	IIa	C-EO

Existing CIED lead management

Recommendations	COR	LOE
Leaving the lead in a condition that will permit future extraction and prevents retraction into the vessel is recommended for any abandoned lead.	I	C-EO
Careful consideration with the patient on the decision on whether to abandon or remove a lead is recommended before starting the procedure. The risks and benefits of each course of action should be discussed, and any decision should take the patient's preference, comorbidities, future vascular access, and available programming options into account.	I	C-EO
Lead abandonment or removal can be a useful treatment strategy if a lead becomes clinically unnecessary or nonfunctional.	IIa	B-NR

This information is directly from the 2017 HRS Consensus Statement.¹

CIED infection

Recommendations	COR	LOE
Evaluation by physicians with specific expertise in CIED infection and lead extraction is recommended for patients with documented CIED infection.	I	C-EO
If antibiotics are going to be prescribed, drawing at least 2 sets of blood cultures before starting antibiotic therapy is recommended for all patients with suspected CIED infection to improve the precision and minimize the duration of antibiotic therapy.	I	C-LD
Gram stain and culture of generator pocket tissue and the explanted lead(s) are recommended at the time of CIED removal to improve the precision and minimize the duration of antibiotic therapy.	I	C-LD
Preprocedural transesophageal echocardiography is recommended for patients with suspected systemic CIED infection to evaluate the absence or size, character, and potential embolic risk of identified vegetations.	I	B-NR
Transesophageal echocardiography can be useful for patients with CIED pocket infection with and without positive blood cultures to evaluate the absence or size, character, and potential embolic risk of identified vegetations.	IIa	B-NR

This information is directly from the 2017 HRS Consensus Statement.¹

Treatment

CIED infection

Recommendations	COR	LOE
Evaluation by physicians with specific expertise in CIED infection and lead extraction can be useful for patients with suspected CIED infection.	IIa	C-EO
Additional imaging may be considered to facilitate the diagnosis of CIED pocket or lead infection when it cannot be confirmed by other methods.	IIb	C-LD
A complete course of antibiotics based on identification and in vitro susceptibility testing results after CIED removal is recommended for all patients with definite CIED system infection.	I	B-NR
Complete device and lead removal is recommended for all patients with definite CIED system infection.	I	B-NR
Complete removal of epicardial leads and patches is recommended for all patients with confirmed infected fluid (purulence) surrounding the intrathoracic portion of the lead.	I	C-EO
Complete device and lead removal is recommended for all patients with valvular endocarditis without definite involvement of the lead(s) and/or device.	I	B-NR

This information is directly from the 2017 HRS Consensus Statement.¹

CIED infection

Recommendations	COR	LOE
Complete device and lead removal is recommended for patients with persistent or recurrent bacteremia or fungemia despite appropriate antibiotic therapy and no other identifiable source for relapse or continued infection.	I	B-NR
Careful consideration of the implications of other implanted devices and hardware is recommended when deciding on the appropriateness of CIED removal and for planning treatment strategy and goals.	I	C-EO

“Delayed, inappropriate, or incomplete therapy can result in significant morbidity and mortality for patients with CIED infection.¹”

- Fred M. Kusumoto, M.D.

Treatment

Risk factors for CIED infection

Patient-related factors	Procedure-related factors	Microbe-related factors
<ul style="list-style-type: none">• Age• Chronic kidney disease• Hemodialysis• Diabetes mellitus• Heart failure• Chronic obstructive pulmonary disease• Preprocedure fever• Malignancy• Skin disorder• Immunosuppressive drug• Prior CIED infection• Anticoagulation	<ul style="list-style-type: none">• Pocket reintervention (generator change, upgrade, lead or pocket revision)• Pocket hematoma• Longer procedure duration• Inexperienced operator• ICD (compared with PM)• Lack of use of prophylactic antibiotics	<ul style="list-style-type: none">• Highly virulent microbes (e.g., staphylococci)

Indications for lead extraction (non-infectious)

Recommendations	COR	LOE
Device and/or lead removal can be useful for patients with severe chronic pain at the device or lead insertion site or believed to be secondary to the device, which causes significant patient discomfort, is not manageable by medical or surgical techniques, and for which there is no acceptable alternative.	IIa	C-EO
Lead removal is recommended for patients with clinically significant thromboembolic events attributable to thrombus on a lead or a lead fragment that cannot be treated by other means.	I	C-EO
Lead removal is recommended for patients with SVC stenosis or occlusion that prevents implantation of a necessary lead.	I	C-EO
Lead removal is recommended for patients with planned stent deployment in a vein already containing a transvenous lead, to avoid entrapment of the lead.	I	C-EO
Lead removal as part of a comprehensive plan for maintaining patency is recommended for patients with SVC stenosis or occlusion with limiting symptoms.	I	C-EO

This information is directly from the 2017 HRS Consensus Statement.¹

Treatment

Indications for lead extraction (non-infectious)

Recommendations	COR	LOE
Lead removal can be useful for patients with ipsilateral venous occlusion preventing access to the venous circulation for required placement of an additional lead.	IIa	C-LD
Lead removal is recommended for patients with life-threatening arrhythmias secondary to retained leads.	I	C-EO
Lead removal can be useful for patients with a CIED location that interferes with the treatment of a malignancy.	IIa	C-EO
Lead removal can be useful for patients if a CIED implantation would require more than 4 leads on one side or more than 5 leads through the SVC.	IIa	C-LD
Lead removal can be useful for patients with an abandoned lead that interferes with the operation of a CIED system.	IIa	C-EO
Lead removal may be considered for patients with leads that due to their design or their failure pose a potential future threat to the patient if left in place.	IIb	C-LD

Indications for lead extraction (non-infectious)

Recommendations	COR	LOE
Lead removal may be considered for patients to facilitate access to MRI.	IIb	C-EO
Lead removal may be considered in the setting of normally functioning nonrecalled pacing or defibrillation leads for selected patients after a shared decision-making process.	IIb	C-EO

Periprocedural management: preparatory phase

Perform a comprehensive history and physical exam

- Perform anticoagulation management
- Optimize hemodynamics
- Confirm the appropriate indications for extraction
- Perform the CIED interrogation
 - Indicate lead model numbers, noting any lead that requires special consideration
 - Confirm lead implant dates
 - Identify prior abandoned leads and implant dates
 - Assess pacemaker dependency
 - Turn off rate-adaptive programming
- Obtain the preprocedural imaging when clinically appropriate. Options include the following:
 - Chest radiography (both posteroanterior and lateral) to assess lead position, identify the presence of abandoned leads, and confirm lead type
 - Echocardiogram to assess LV function, identify intracardiac masses/vegetations, evaluate valve function and whether a patent foramen ovale is present, and identify intracardiac lead course and presence of pleural or pericardial effusions
 - Cardiac CT to assess extravascular or extracardiac lead positioning and potentially identify sites of venous adhesions
 - Fluoroscopy to identify sites of venous occlusion or stenosis and assess regions of lead mobility and adherence

This information is directly from the 2017 HRS Consensus Statement.¹

- Define the extraction approach and procedure goals
 - Percutaneous versus open extraction
 - Hybrid approach to the extraction
 - Goal of single versus multiple lead removal or complete system removal
 - Minimizing damage to nontargeted leads
- Determine the postextraction plan
 - Indications for CIED reimplantation
 - Timing of CIED reimplantation
- Obtain the patient's informed consent

Outcomes and follow-up

Recommendation	COR	LOE
Extraction programs and operator-specific information on volume, clinical success rates, and complication rates for lead removal and extraction should be available and discussed with the patient prior to any lead removal procedure.	I	C-EO

Patient clinical scenarios

Patient scenario #1

A 52-year-old man with a history of complete heart block, leading to a diagnosis of cardiac sarcoidosis, underwent dual-chamber ICD with a single-coil ICD lead 4 years ago. He has had ATP therapy for VT. Remote interrogation shows impedance of 150 and episodes of noise on RV lead. Noise is reproducible on exam with pocket manipulation.

Management strategies

- Management options discussed included addition of new RV pace-sense lead; and ICD lead extraction and replacement.
- Values elicited during discussion included his desire for a reliable system, concerns about the effect of more leads in his vasculature, and his desire to be able to easily undergo MRI in the future.
- The decision was made to extract and reimplant a new ICD lead.

Key points

- Should the strategy of an additional lead be applied, vein patency would need to be considered. In case of extraction and reimplantation, the lead's original insertion point would need to be evaluated in case this represents damage from the costoclavicular ligaments.
- Adding a pace-sense lead is sometimes a suboptimal choice, because the ICD shock coil can also be at high risk of failure in the setting of a pace-sense component fracture.

Patient scenario #2

An 86-year-old man with complete heart block who underwent dual-chamber pacemaker implantation 14 years ago, with most recent generator replacement 3 years ago. Two leads are in place. His medical history is significant for chronic lymphocytic lymphoma and recently diagnosed prostate cancer. He presents with noise on the right ventricular lead and inhibition of ventricular pacing consistent with lead malfunction.

Management strategies

- Assess possibility of reprogramming to unipolar.
- Consider likelihood of ipsilateral venous occlusion, which would require contralateral lead placement for addition.
- Management options discussed included extraction of 14-year-old pacemaker lead with new lead implantation versus abandonment of old lead and placement of new right ventricular lead.
- Values elicited in discussion included patient's desire to avoid hospitalization and not wanting to be dependent on his children.
- Although the risks of lead addition and lead extraction are comparable in the literature, the risk of major complications and a more prolonged hospital stay appear higher for an extraction procedure, particularly given the patient's advanced age, comorbidities, and older leads. The decision was made to add a new pace-sense lead and abandon the previously placed lead.

Key points

- Age and medical comorbidities contribute to the lead management decision-making.
- Lead type and dwell time contribute to the risk and benefit analysis in lead management decision-making.
- Abandoned leads are a contraindication for MRI, which is often used in the follow-up of cancer.

This information is directly from the 2017 HRS Consensus Statement.¹

Patient clinical scenarios

Patient scenario #3

A 46-year-old woman with a history of mechanical mitral valve replacement complicated by complete heart block, who underwent placement of a dual-chamber pacemaker 3 years ago. She presents with dislodgement of the atrial lead associated with symptoms of loss of AV synchrony.

Management strategies

- Management options discussed included extraction and replacement of atrial lead, attempt to reposition, and addition of new atrial lead.
- Values elicited in discussion included the desire to have the best possible functional CIED system and not have abandoned leads, even if this resulted in a longer hospital stay due to anticoagulation management.
- Despite the mechanical mitral valve, the ease of extraction of a 3-year-old pacemaker lead is reasonable. The decision was made to extract and replace the lead.

Key points

- Young age and long-term need for functional CIED therapy and the desire to avoid an abandoned lead contributed to the decision-making process

Patient scenario #4

A 25-year-old man who underwent a secondary prevention ICD placement with a dual-coil lead 14 years ago for a ventricular fibrillation cardiac arrest. His ICD lead fractured 6 years ago, and he underwent addition of a new ICD lead and abandonment of his first ICD lead. During the follow-up, the new ICD lead was found to be fractured, with inappropriate detections due to noise.

Management strategies

- Management options discussed included adding a third lead; abandoning both transvenous ICD leads and implanting a subcutaneous ICD; extracting both leads and adding a new ICD lead; extracting both leads and implanting a subcutaneous ICD.
- Primary concerns elicited were the potential for long-term complications from the ICD leads and the possibility of needing an MRI in his lifetime. The decision was made to extract both leads and implant a subcutaneous ICD lead, after discussing the risks and benefits of a subcutaneous ICD system versus a transvenous ICD system.

Key points

- The lead extraction procedure was higher risk due to the previous decision to abandon a malfunctioning lead in a young patient.

Patient clinical scenarios

Patient scenario #5

A 40-year-old woman with familial LQT2 who underwent primary prevention ICD placement with a dual-coil lead 8 years ago due to pregnancy, concerns about increased risk of arrhythmias during the postpartum setting, and strong family history of peripartum sudden death. She has two children, will not have future pregnancies, and has never had ICD therapies. ICD generator is ERI, and she no longer wants ICD therapy.

Management strategies

- Management options discussed included abandoning lead and generator; removing generator and abandoning lead; and extracting lead and generator.
- Values elicited included a desire to not have a prolonged hospitalization or recovery and not wanting a generator in the pocket.
- The patient did not want to undergo extraction. At her request, the decision was made to remove the generator and abandon the lead.

Key points

- The option of removing only the generator would leave the patient with a contraindication for MRI.
- The patient remains at ongoing risk for lead infection, which would require a higher risk extraction in the future.
- Opening the pocket to remove the generator exposed the patient to a risk of infection.

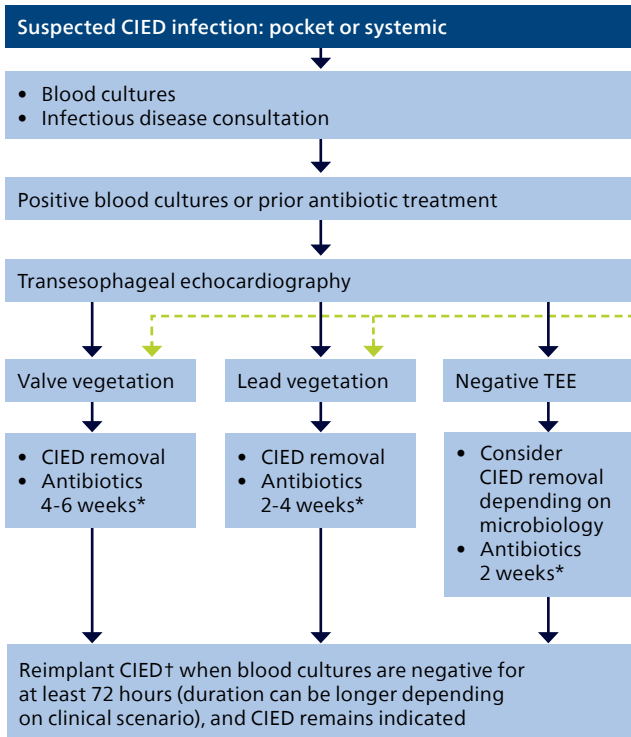
Lead extraction procedure-related complications

Procedure	Incidence %
Major	0.19%-1.80%
Death	0.19%-1.20%
Cardiac avulsion	0.19%-0.96%
Vascular laceration	0.16%-0.41%
Respiratory arrest	0.20%
Cerebrovascular accident	0.07%-0.08%
Pericardial effusion requiring intervention	0.23%-0.59%
Hemothorax requiring intervention	0.07%-0.20%
Cardiac arrest	0.07%
Thromboembolism requiring intervention	0.07%
Flail tricuspid valve leaflet requiring intervention	0.03%
Massive pulmonary embolism	0.08%
Minor	0.60%-6.20%
Pericardial effusion without intervention	0.07%-0.16%
Hematoma requiring evacuation	0.90%-1.60%
Venous thrombosis requiring medical intervention	0.10%-0.21%
Vascular repair at venous entry site	0.07%-0.13%
Migrated lead fragment without sequelae	0.20%
Bleeding requiring blood transfusion	0.08%-1.00%
AV fistula requiring intervention	0.16%
Coronary sinus dissection	0.13%
Pneumothorax requiring chest tube	1.10%
Worsening tricuspid valve function	0.32%-0.59%
Pulmonary embolism	0.24%-0.59%

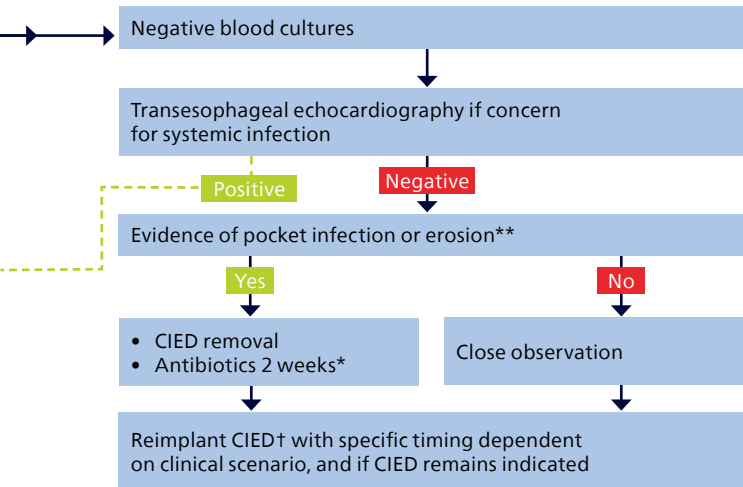
This information is directly from the 2017 HRS Consensus Statement.¹

Infection diagnosis and treatment

Figure 1. Management of suspected CIED infection



This information is directly from the 2017 HRS Consensus Statement.¹



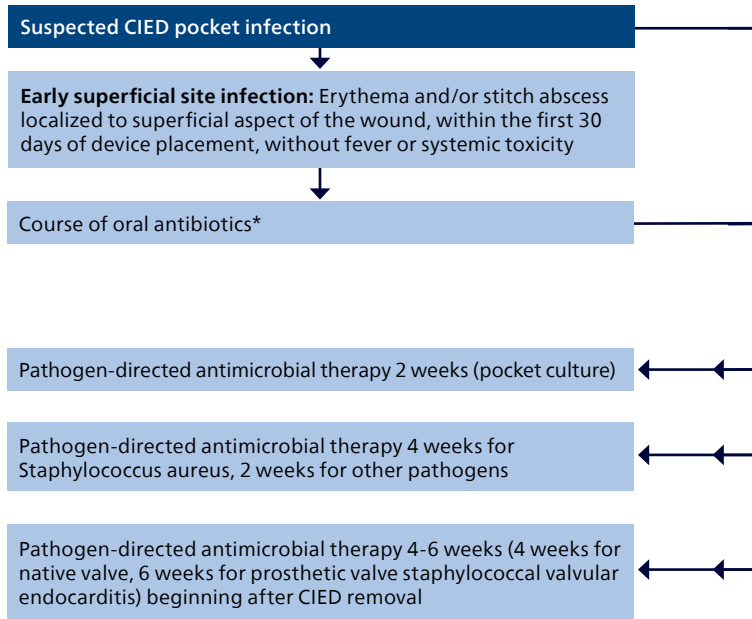
*Refer to text and table for specific recommendations depending on microbiology. Antimicrobial therapy should be at least 4-6 weeks for endocarditis (4 weeks for native valve, 6 weeks for prosthetic valve or staphylococcal valvular endocarditis). If lead vegetation is present in the absence of a valve vegetation, 4 weeks of antibiotics for *Staphylococcus aureus* and 2 weeks for other pathogens is recommended.

**2010 AHA CIED Infection Update distinguishes between pocket infection and erosion (Baddour et al. *Circulation* 2010;121:458-477).

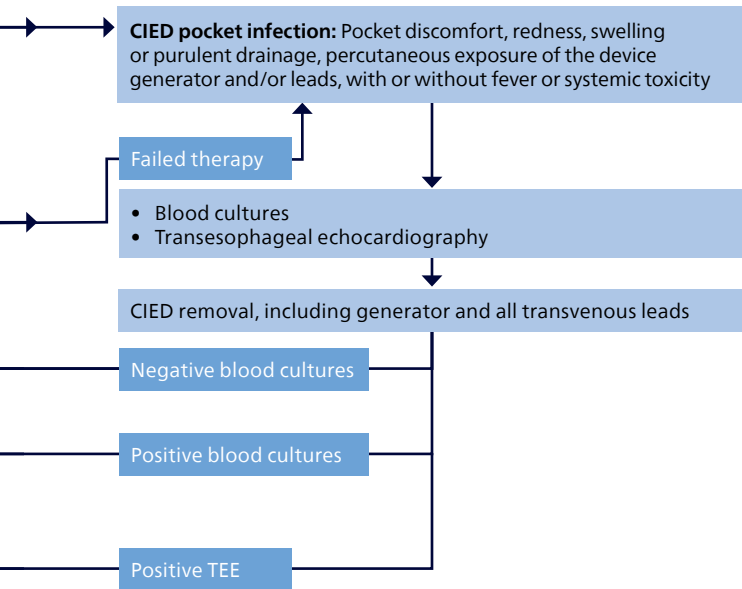
†Usually the contralateral side; a subcutaneous ICD may also be considered.

Infection diagnosis and treatment

Figure 2. Management of suspected pocket infection



This information is directly from the 2017 HRS Consensus Statement.¹

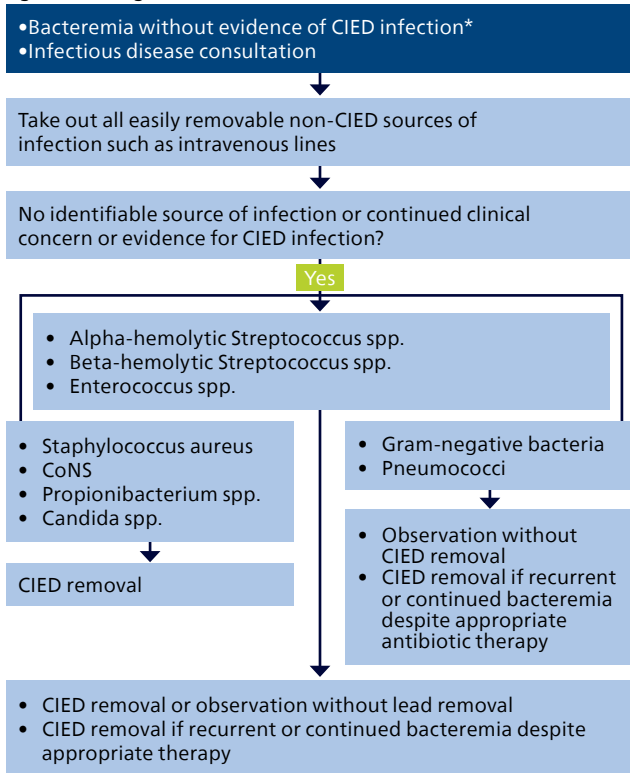


*See full text of the consensus statement for examples.

This information is directly from the 2017 HRS Consensus Statement.¹

Infection diagnosis and treatment

Figure 3. Management of bacteremia without evidence of CIED infection



This information is directly from the 2017 HRS Consensus Statement.¹

Abbreviations

ATP	Antitachycardia pacing
AV	Atrioventricular
CIED	Cardiovascular implantable electronic device
COR	Class of recommendation
Cr	Creatinine
CRP	C-reactive protein
CT	Computed tomography
EGM	Electrogram
ERI	Elective replacement indicator
ESRD	End-stage renal disease
ICD	Implantable cardioverter defibrillator
INR	International normalized ratio
LOE	Level of evidence
LV	Left ventricle
MRI	Magnetic resonance imaging
PM	Pacemaker
RV	Right ventricle
SVC	Superior vena cava
TEE	Transesophageal echocardiography
VT	Ventricular tachycardia

*Important to distinguish between bloodstream infection and contamination in bacteremia involving skin flora.

This information is directly from the 2017 HRS Consensus Statement.¹

References

1. Kusumoto et al. 2017 HRS Expert Consensus Statement on Cardiovascular Implantable Electronic Device Lead Management and Extraction. Heart Rhythm, 2017.
2. Wilkoff, B.L., et al. (2009). Transvenous lead extraction: Heart Rhythm Society expert consensus on facilities, training, indications, and patient management: this document was endorsed by the American Heart Association (AHA). Heart Rhythm, 6(7), 1085-1104.

