

Phoenix with IVUS case reviews Performed by Dr. William H. Crowder Jackson, MS

The materials made available are for training, educational and informational purposes only and not for the purpose of providing legal, medical, regulatory or other professional advice. Individual results may vary depending on a variety of patient-specific attributes and related factors.


Patient presentation

65-year-old female referred due to life-style limiting claudication with a history of:

- Previous tobacco use
 - Controlled diabetes
 - Hypertension
-
- Referred due to life-style limiting claudication
 - Could walk for very short distances and had resting pain
 - Underwent non-invasive peripheral arterial studies prior to our assessment which demonstrated a left superficial femoral artery stenosis

Initial angiogram

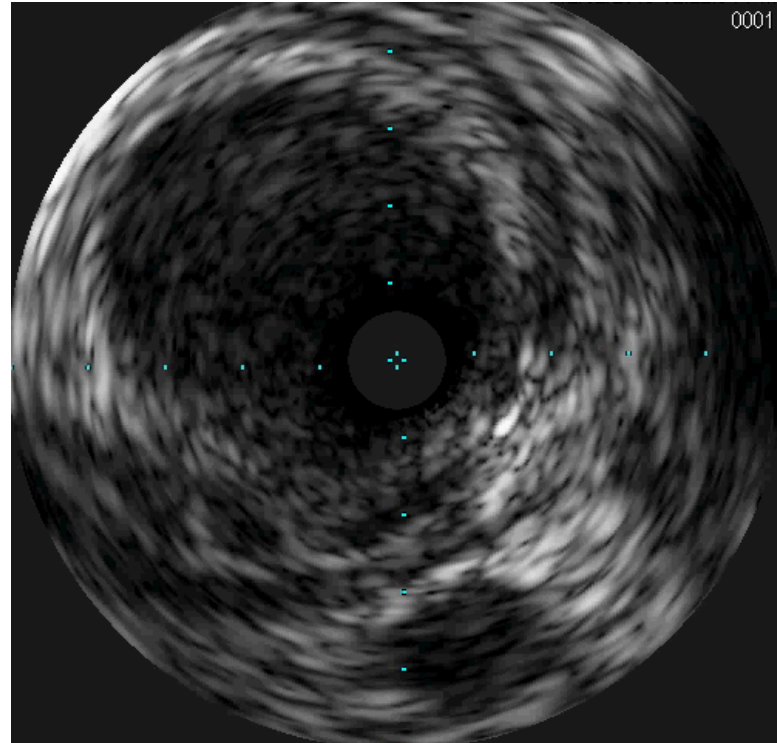
Right superficial femoral
artery/popliteal stenosis



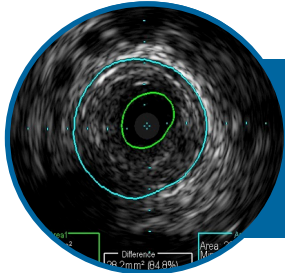
Initial IVUS pullback

IVUS determined:

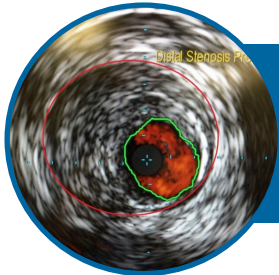
- Location and length of plaque to aid in therapy decision
- Plaque morphology suitable for atherectomy with Phoenix



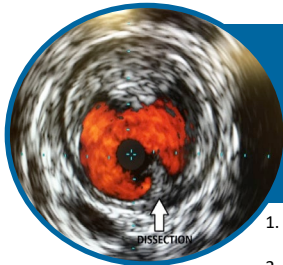
IVUS guidance benefits patients



IVUS provides information regarding measurements of lumen and vessel size, plaque area and volume, and the location of key anatomical landmarks.



Study data suggests that determination of overall vessel diameter and interpretation of plaque morphology by angiography are discordant from IVUS-derived data.¹



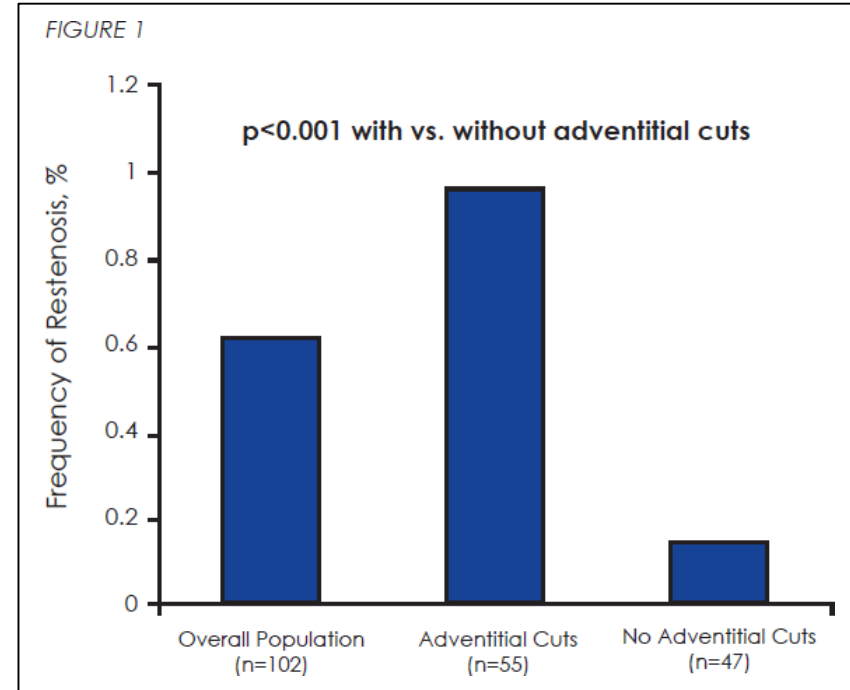
Study data suggests that IVUS is able to provide evidence that a significant portion of the plaque has been removed during atherectomy procedures.²

1. Arthurs ZM, Bishop PD, Feiten LE, Eagleton MJ, Clair DG, Kashyap VS. Evaluation of peripheral atherosclerosis: a comparative analysis of angiography and intravascular ultrasound imaging. *J Vasc Surg.* 2010 Apr;51(4):933-8; discussion 939.
2. Lee JT, Fang TD, White RA. Applications of intravascular ultrasound in the treatment of peripheral occlusive disease. *Semin Vasc Surg.* 2006 Sep;19(3):139-44.

UTOPIA results

Results:

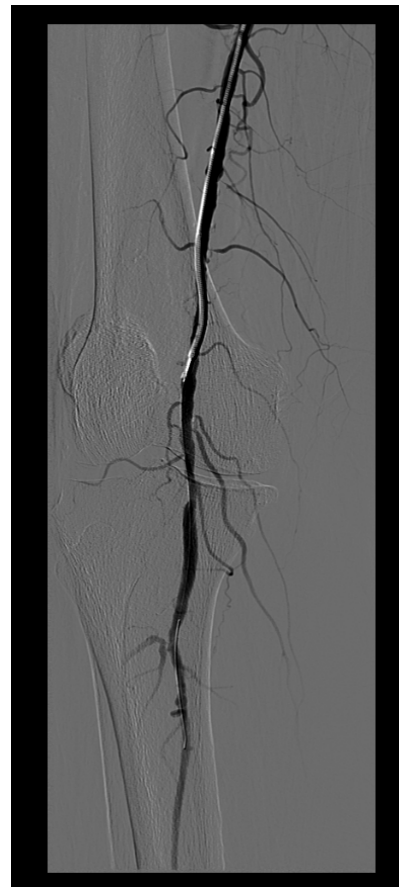- Adventitial cuts identified in 54% of patients
- One year overall incidence of restenosis was 62%
- **96.4%** restenosis rate was observed in patients with adventitial cuts vs. a **14.9%** restenosis rate without adventitial cuts ($p < 0.001$)



UTOPIA Trial: J Am Coll Cardiol. 2012; 59(13s1):E2083-E2083. doi:10.1016/S0735-1097(12)62084-1

Phoenix 2.4 mm deflecting catheter

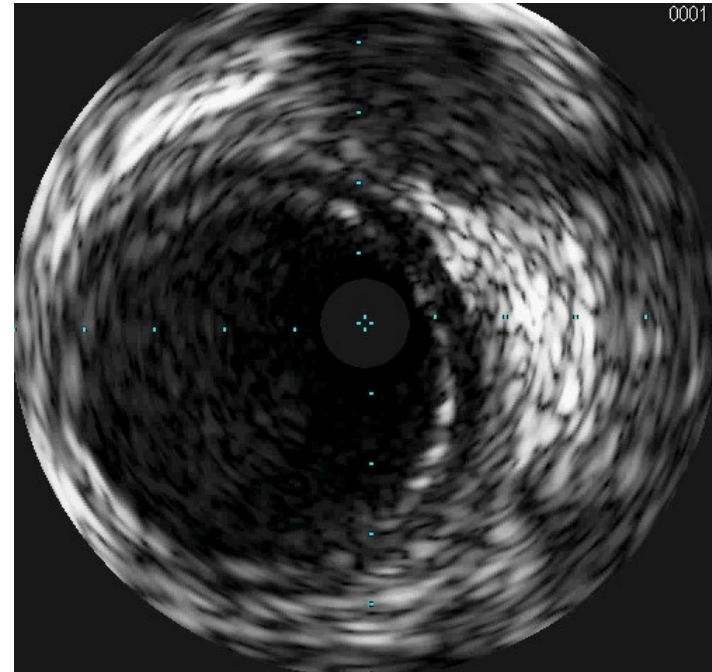
- Atherectomy performed by Phoenix 2.4 mm x 127 cm device
- Five debulking runs performed in under four minutes
- Straight channel cut initially, then catheter tip deflected and rotated as needed to debulk the lesion
- Deflecting mechanism of action allowed physician to control the angle of the cut
- Post angioplasty performed



Post-IVUS after Phoenix atherectomy


IVUS after 2.4 mm deflecting Phoenix atherectomy demonstrated:

- Large luminal gain achieved without adventitial injury or major dissections



Final angiogram

Final angiogram post IVUS, Phoenix, and PTA demonstrates adequate result for the patient



Conclusion

Phoenix solution:

- The Phoenix atherectomy system continuously debulked material with just one catheter insertion
- Deflecting mechanism of action allowed the physician to control the angle of the cut

IVUS solution:

- IVUS utilized to understand the location of the lesion and morphology to assist in determining a suitable therapy for the patient
- IVUS determined that large luminal gain was achieved without adventitial injury or major dissections

