

**PHILIPS**

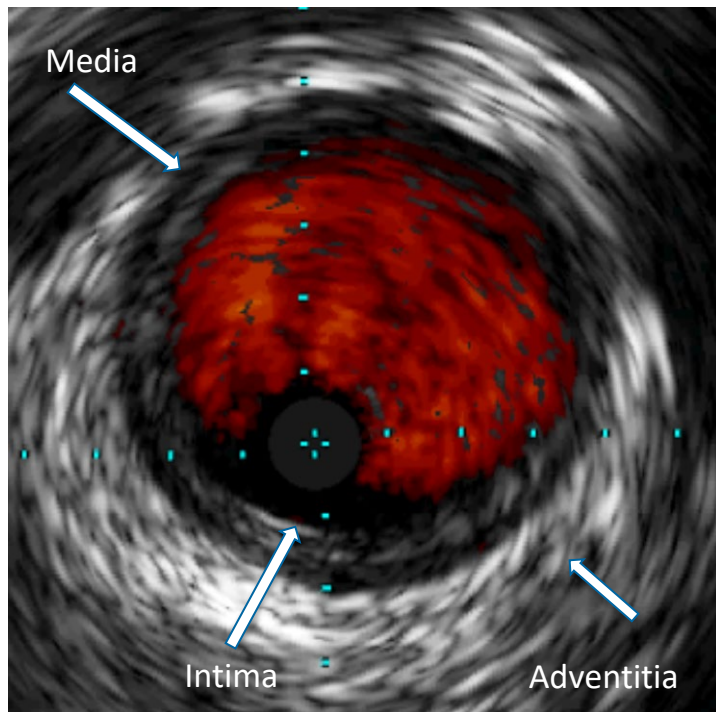
[www.philips.com](http://www.philips.com)

# Atherectomy and IVUS

The materials made available are for training, educational and informational purposes only and not for the purpose of providing legal, medical, regulatory or other professional advice. Individual results may vary depending on a variety of patient-specific attributes and related factors.

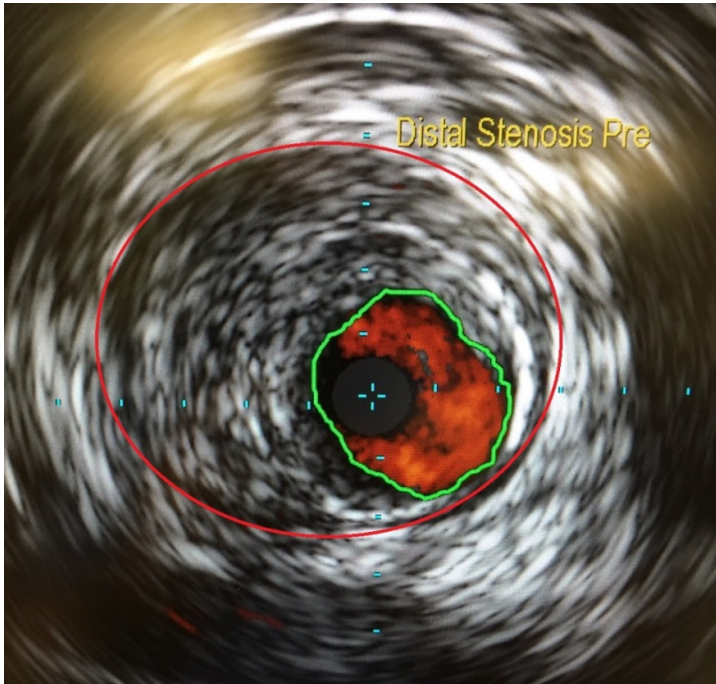
innovation  you

# IVUS image of healthy vessel



Results are not predictive of future outcomes  
Image courtesy of Philips

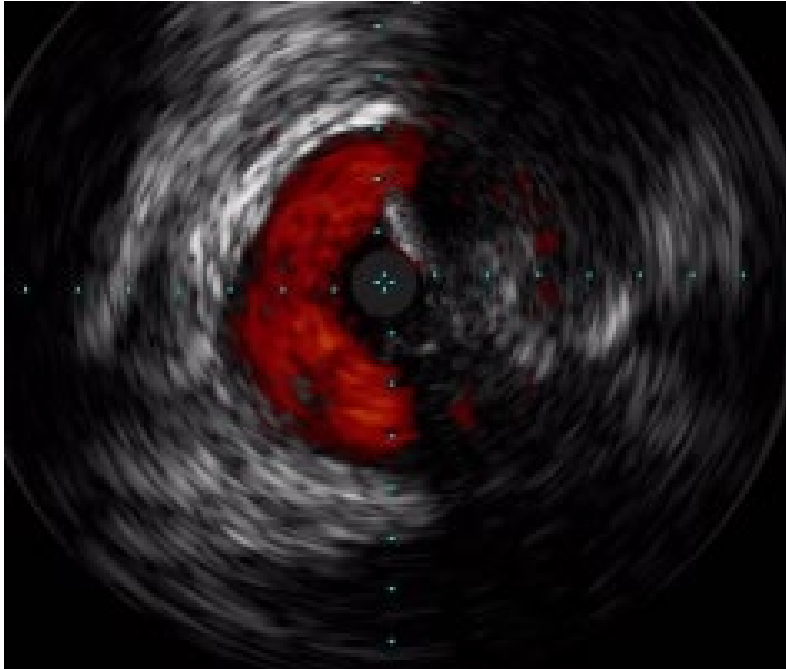
# IVUS image of diseased vessel



Material between the green line (intima) and red line (adventitia) is fibrotic plaque

Results are not predictive of future outcomes  
Image courtesy of Philips

# IVUS post-directional atherectomy

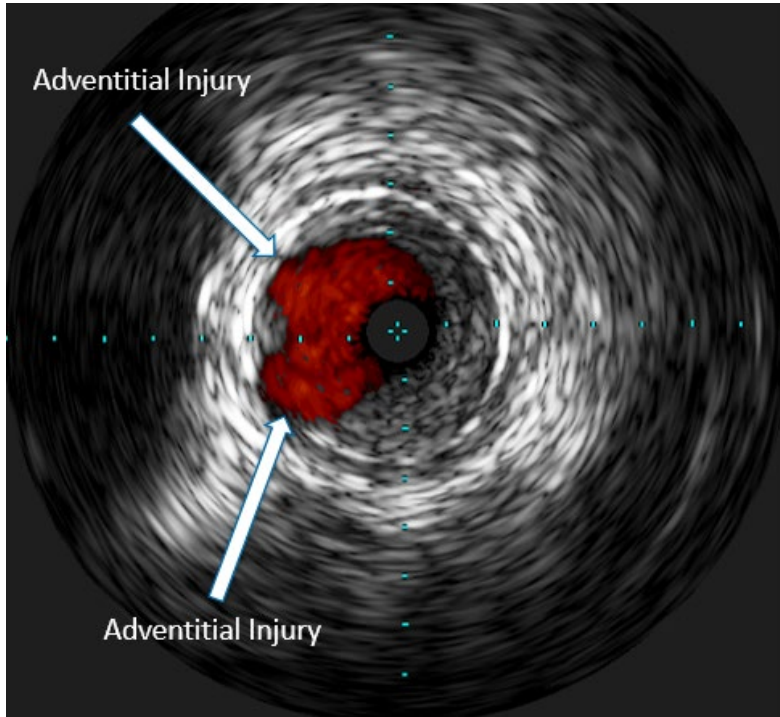


Corresponding IVUS image demonstrates lumen gain at the expense of adventitial injury

Results are not predictive of future outcomes  
Image courtesy of Dr. Eric Dippel

This specific case shows a sub-optimal outcome. However, presented case result may not be indicative of all directional atherectomy case results.

# IVUS post-directional atherectomy

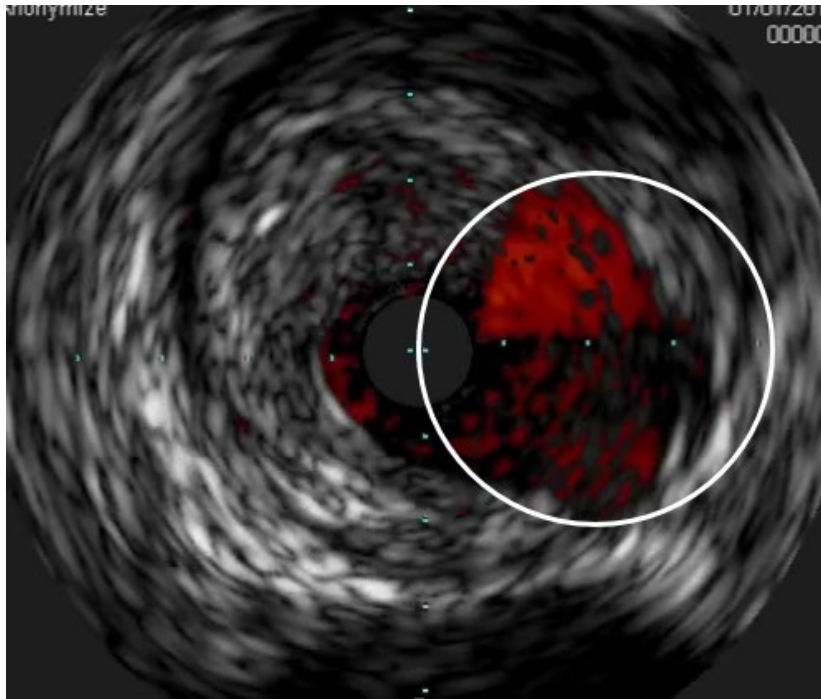


Corresponding IVUS image demonstrates lumen gain at the expense of adventitial injury

Results are not predictive of future outcomes  
Images obtained from actual cases with consent from the clinician  
Data on file at Philips

This specific case shows a sub-optimal outcome. However, presented case result may not be indicative of all directional atherectomy case results

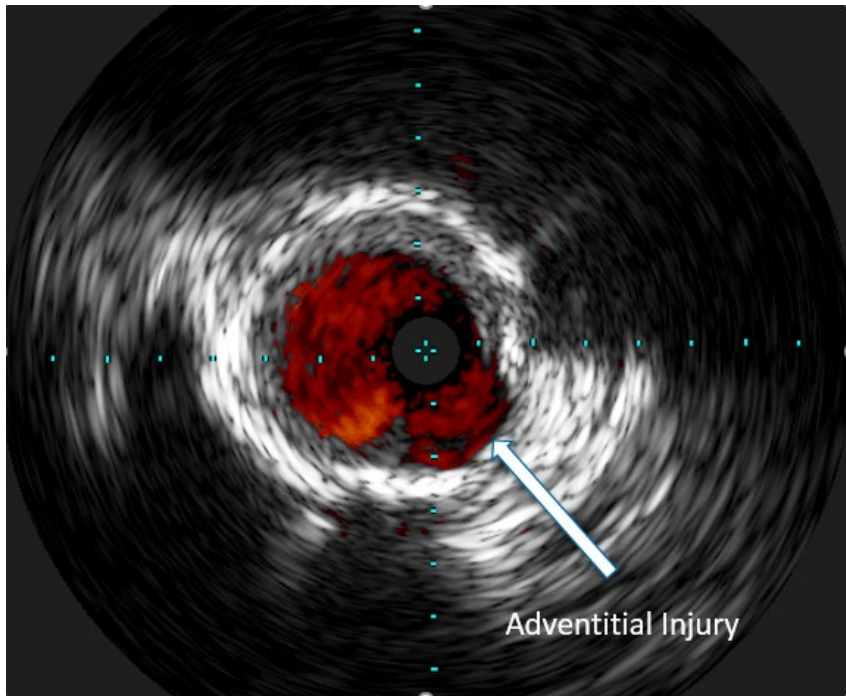
# IVUS post-directional atherectomy



Corresponding IVUS image demonstrates lumen gain at the expense of adventitial injury

Results are not predictive of future outcomes  
Image Courtesy of Dr. Prakash Krishnan

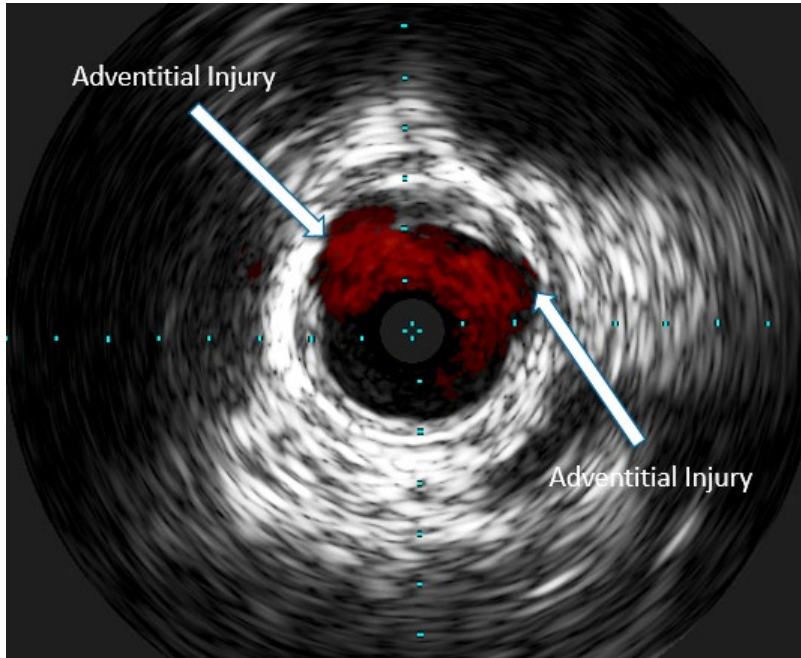
# IVUS post-directional atherectomy



Corresponding IVUS image demonstrates lumen gain at the expense of adventitial injury

Results are not predictive of future outcomes  
Images obtained from actual cases with consent from the clinician  
Data on file at Philips

# IVUS post-directional atherectomy



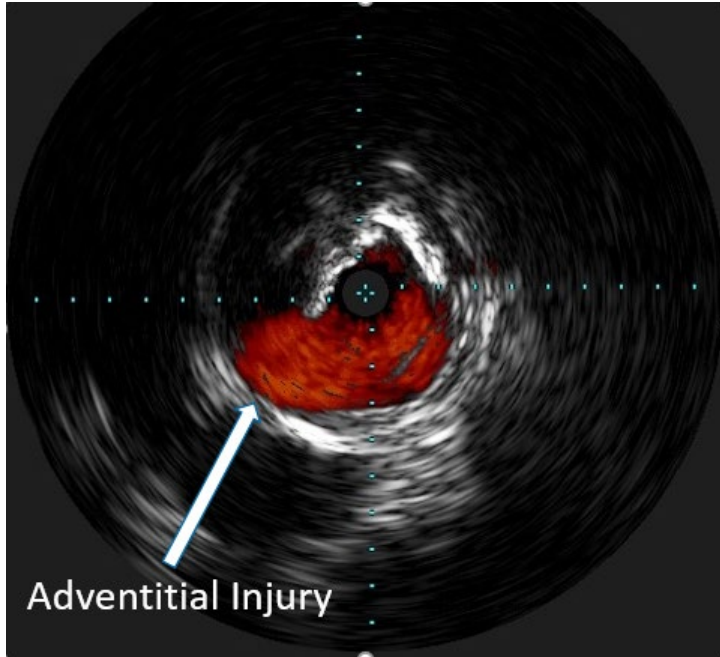
Corresponding IVUS image demonstrates lumen gain at the expense of adventitial injury

Results are not predictive of future outcomes  
Images obtained from actual cases with consent from the clinician  
Data on file at Philips

This specific case shows a sub-optimal outcome. However, presented case result may not be indicative of all directional atherectomy case results



# IVUS post-orbital atherectomy

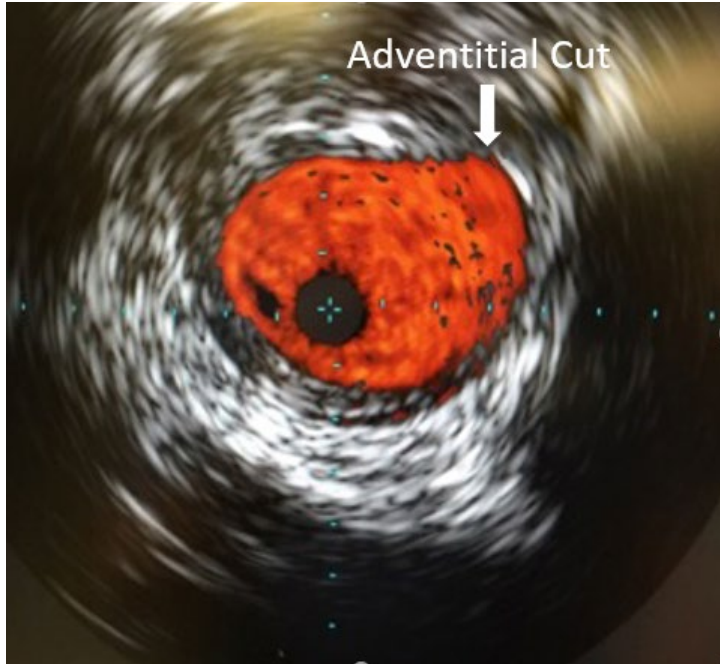


Corresponding IVUS image demonstrates lumen gain at the expense of adventitial injury

Results are not predictive of future outcomes  
IVUS Image Courtesy of Dr. Cezar Staniloae

This specific case shows a sub-optimal outcome. However, presented case result may not be indicative of all directional atherectomy case results

# IVUS post-orbital atherectomy

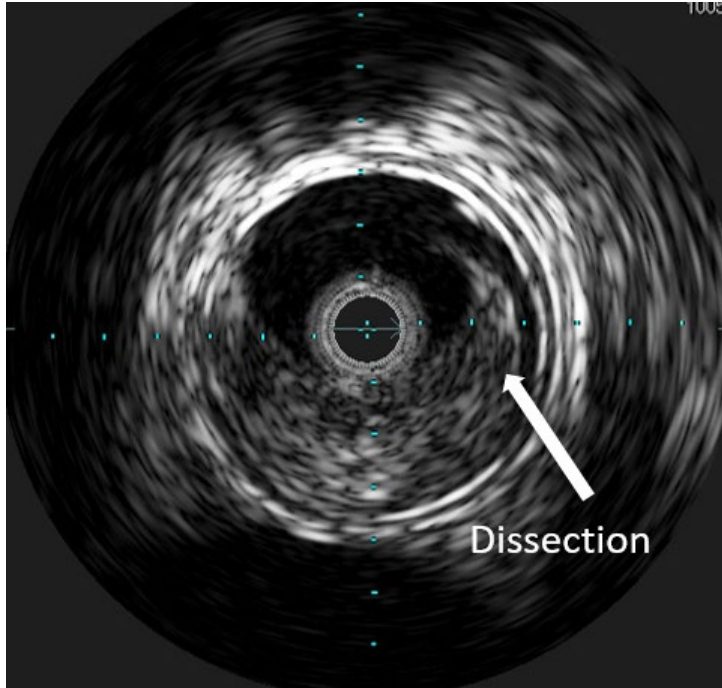


Corresponding IVUS image demonstrates lumen gain at the expense of adventitial injury

Results are not predictive of future outcomes  
Images obtained from actual cases with consent from the clinician  
Data on file at Philips

This specific case shows a sub-optimal outcome. However, presented case result may not be indicative of all directional atherectomy case results

# Dissection with orbital atherectomy

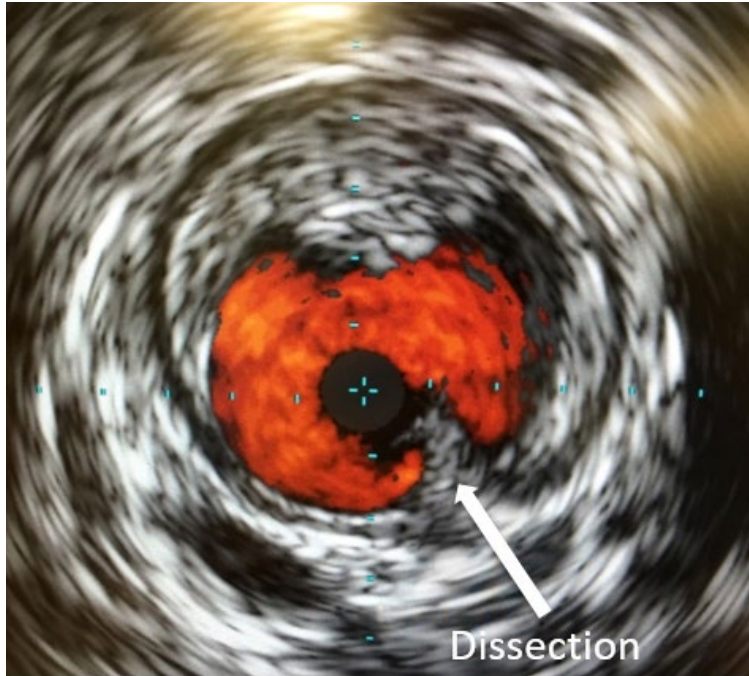


Corresponding IVUS image demonstrates lumen gain at the expense of creating a dissection

Results are not predictive of future outcomes  
IVUS Image Courtesy of Dr. Cezar Staniloae

This specific case shows a sub-optimal outcome. However, presented case result may not be indicative of all directional atherectomy case results

# Lumen gain at expense of a dissection



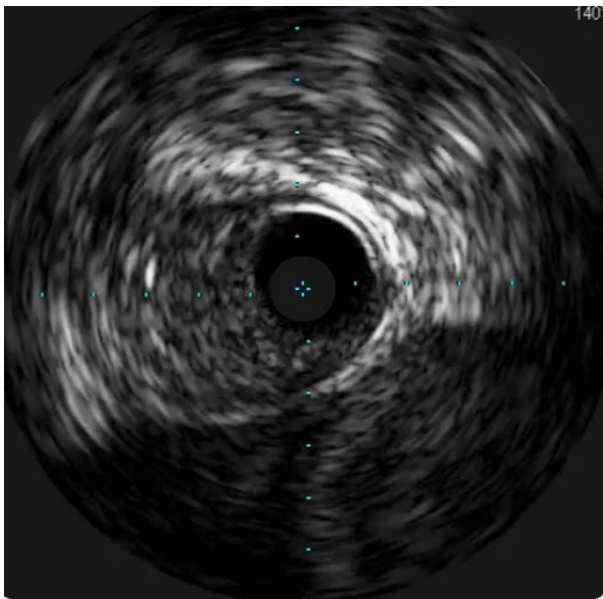
Corresponding IVUS image demonstrates lumen gain at the expense of creating a dissection.

Results are not predictive of future outcomes  
Images obtained from actual cases with consent from the clinician  
Data on file at Philips

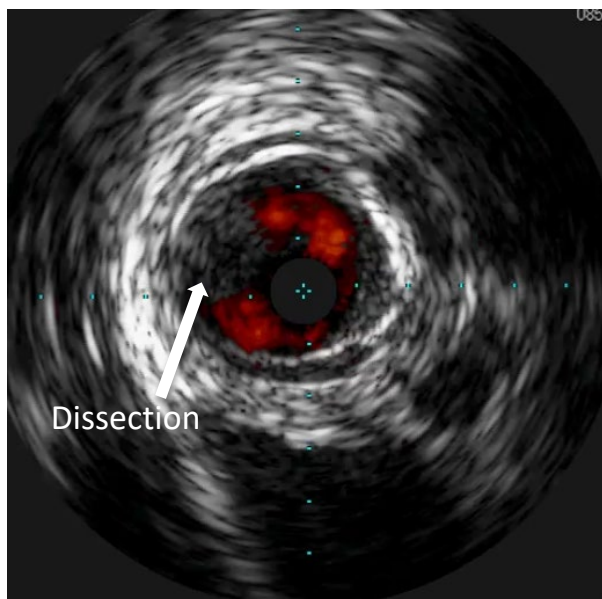
This specific case shows a sub-optimal outcome. However, presented case result may not be indicative of all directional atherectomy case results

# Dissection post-aspirational atherectomy

Pre-aspirational atherectomy



Post-aspirational atherectomy

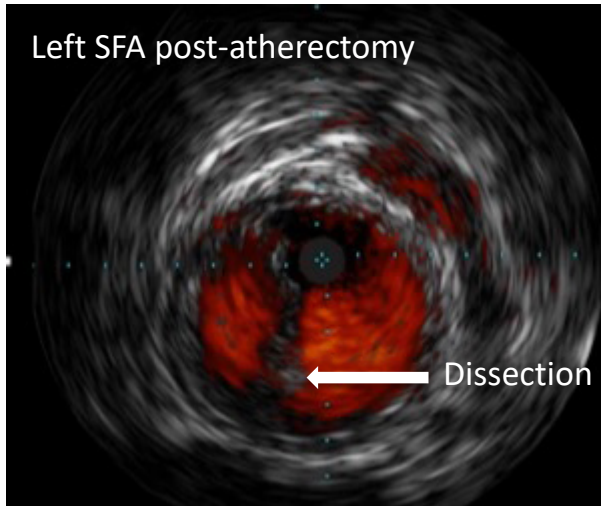


Results are not predictive of future outcomes  
Images obtained from actual cases with  
consent from the clinician  
Data on file at Philips

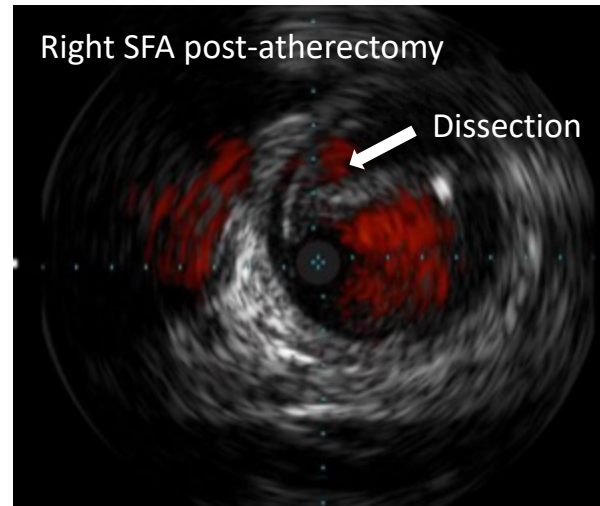
This specific case shows a sub-optimal outcome. However, presented case result may not be indicative of all directional atherectomy case results

# Dissection post-aspirational atherectomy

IVUS with ChromaFlo was used to assess the result post-atherectomy and balloon dilatation



IVUS performed on the left SFA showed localized dissection in the proximal and mid segments of the vessel

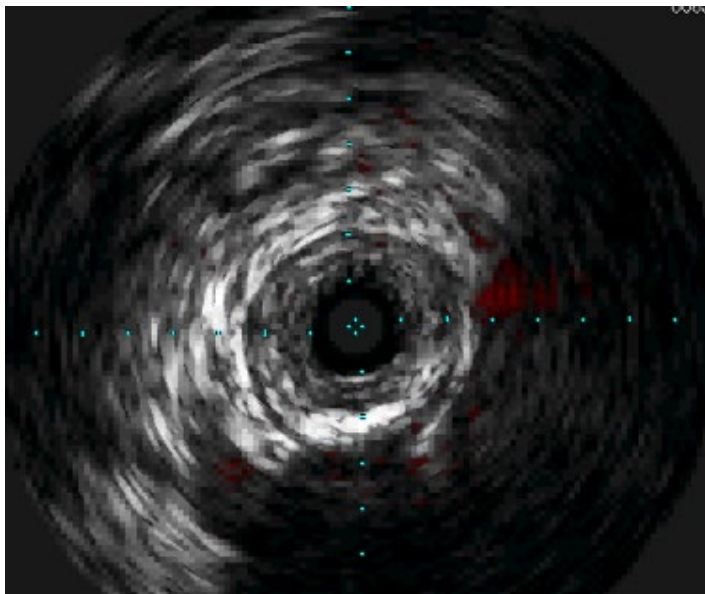


IVUS demonstrated a significant dissection throughout the length of the right SFA

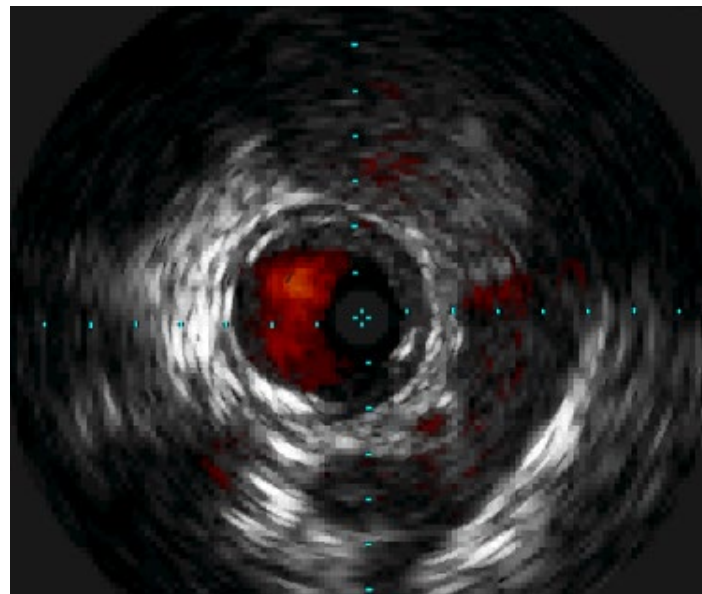
Results are not predictive of future outcomes  
IVUS images provided by Dr. Eric Dippel

This specific case shows a sub-optimal outcome. However, presented case result may not be indicative of all directional atherectomy case results

# IVUS with Phoenix



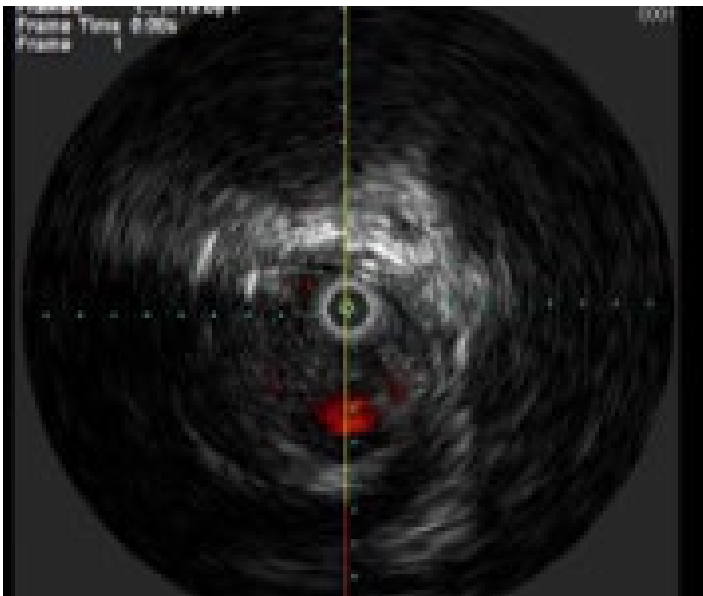
Pre-Phoenix: concentric, calcified fibrotic SFA lesion



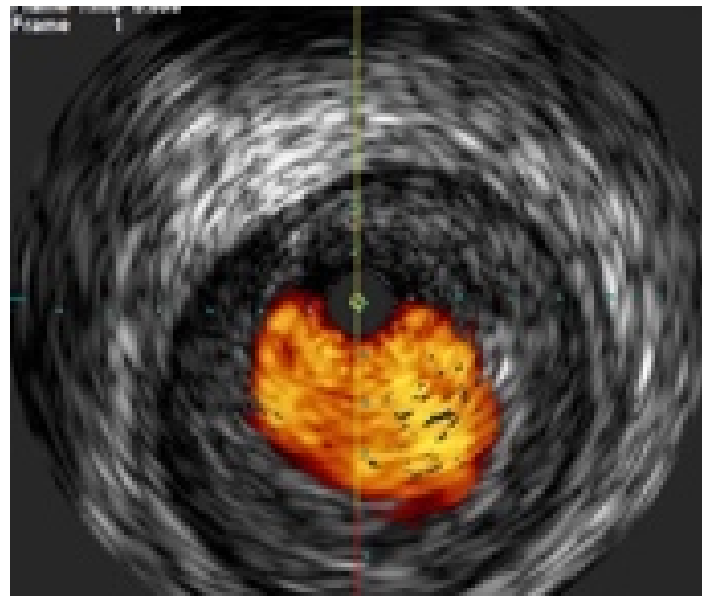
Post-Phoenix: large luminal gain without adventitial injury

Results are not predictive of future outcomes  
Images Courtesy of Dr. Gonzalez

# IVUS with Phoenix



Pre-Phoenix: concentric, non-calcified fibrotic SFA lesion

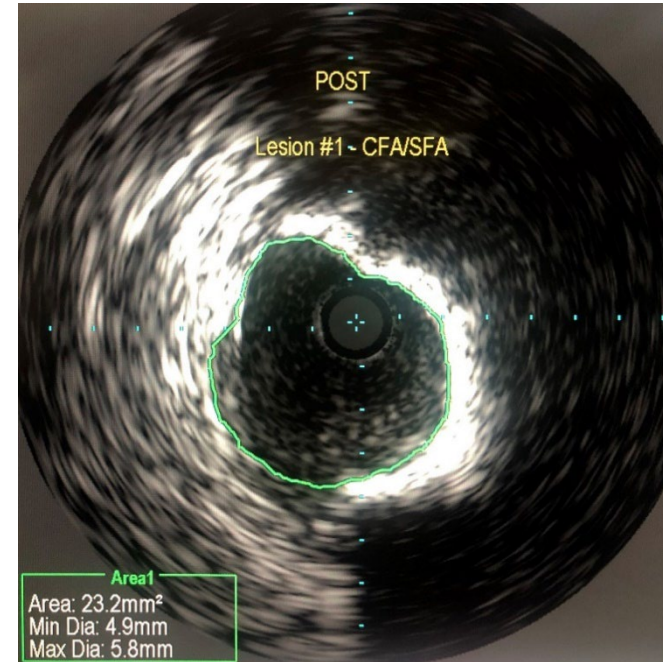
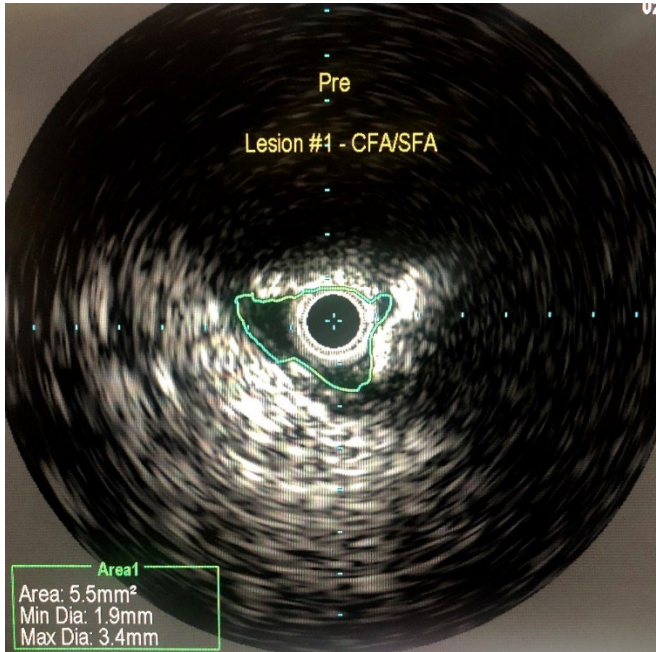


Post-Phoenix: large luminal gain without adventitial injury

Results are not predictive of future outcomes  
Images Courtesy of Dr. Tom Davis

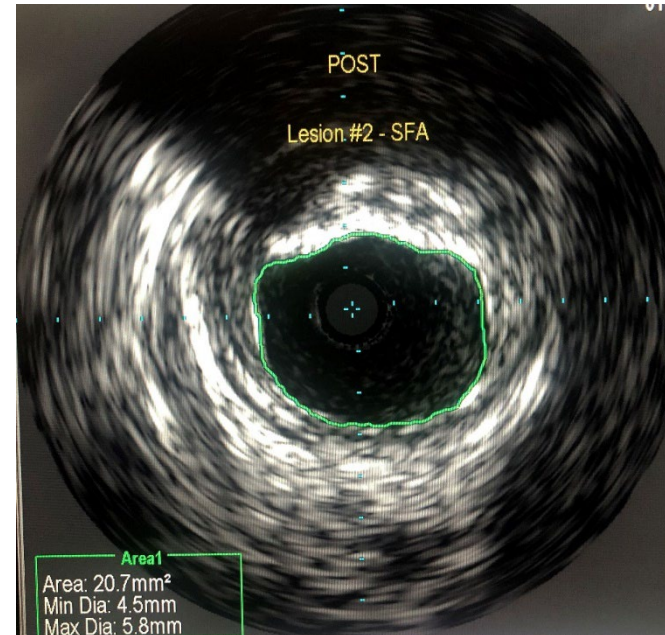
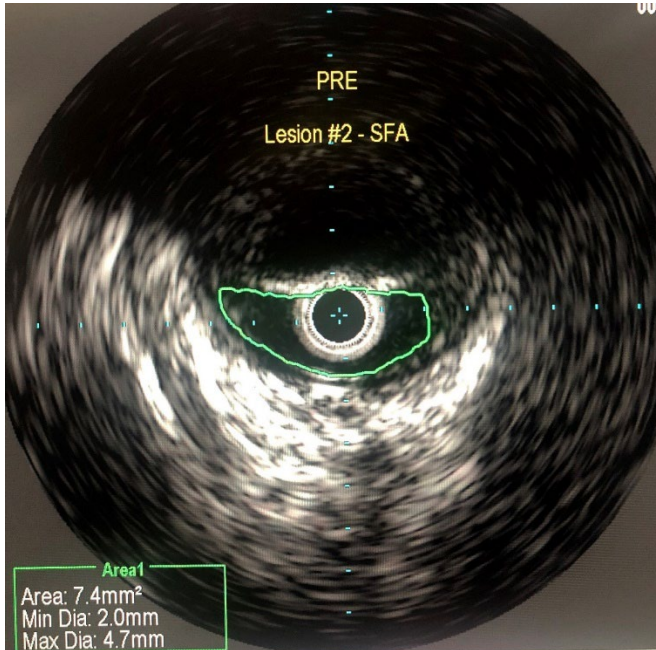


# Pre and post IVUS with 2.2 mm deflecting Phoenix catheter Lesion #1



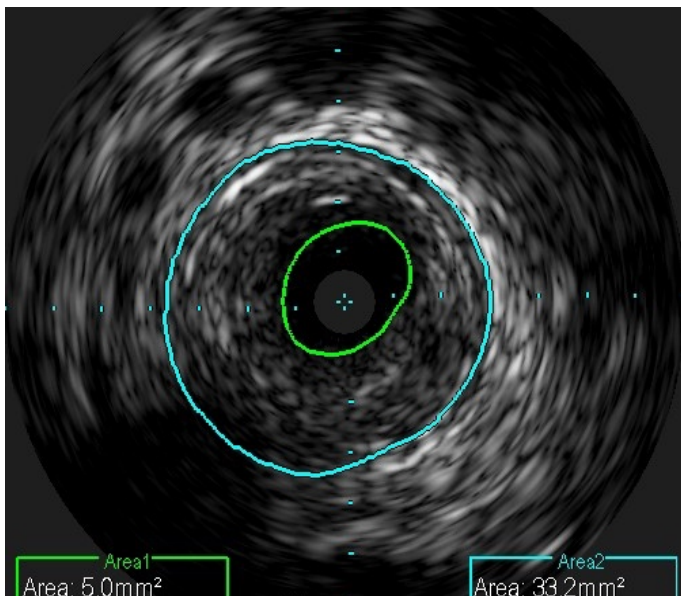
Results are not predictive of future outcomes  
Images Courtesy of Dr. Sarang Mangalmurti

# Pre and post IVUS with 2.2 mm deflecting Phoenix catheter Lesion #2

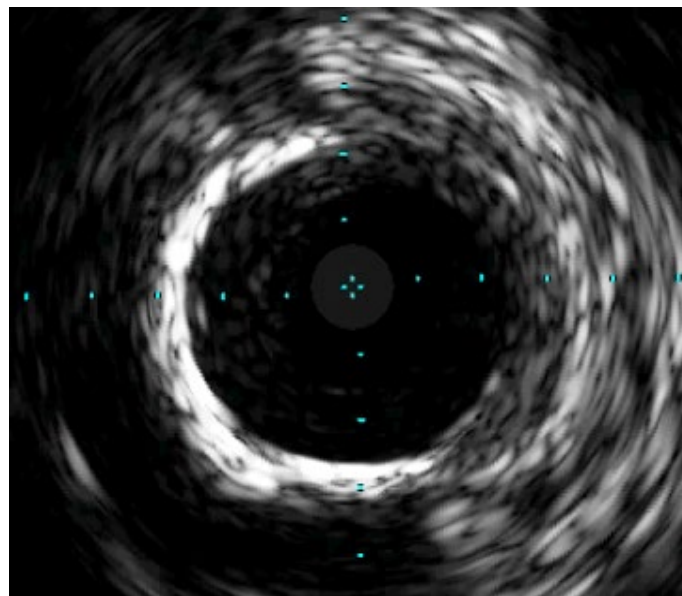


Results are not predictive of future outcomes  
Images Courtesy of Dr. Sarang Mangalmurti

# IVUS with Phoenix



Pre-Phoenix



Post-Phoenix 2.4: large luminal gain  
without adventitial injury

Results are not predictive of future outcomes  
Images Courtesy of Dr. James Bennett



# Phoenix is your atherectomy solution

## Vessel Injury

- Front cutter clears tissue in a way that may help reduce potential trauma to the vessel

## Distal Embolization

- Continuous capture and passive clearance of debulked material into the catheter resulted in a 1% rate of symptomatic distal emboli<sup>1</sup> in the EASE trial

## Ease of Use

- Single insertion - no need to remove and clean out debulked material
- Battery powered handle operated - no capital equipment or additional procedural accessories required

## Deliverability

- Low profile, front cutting design allows for direct lesion access without having to first pass a nosecone
- OTW design aids in trackability and pushability of catheter

## Versatility

- Treat a range of tissue types from soft plaque to calcified arteries
- Treat most peripheral vasculature with only 3 catheter diameters<sup>2</sup>

1. Endovascular Atherectomy Safety and Effectiveness Study (EASE), ClinicalTrials.gov Identifier NCT01541774 (accessed 23Oct2015). Results presented at the Vascular Interventional Advances (VIVA) Conference in October of 2013 (Las Vegas, NV) by Stephen Williams, MD  
2. Phoenix Atherectomy device is indicated for vessels 2.5mm in diameter and above

